

Sleep in right hemispherectomized patients: evidence of electrophysiological compensation

L. McCormick^a, T. Nielsen^a, M. Ptito^b, A. Ptito^b, J.-G. Villemure^b, C. Vera^c, J. Montplaisir^{a,*}

^aLaboratoire du Sommeil, Hôpital du Sacré-Coeur de Montréal, Montréal, Québec, Canada

^bMontréal Neurological Institute, Montréal, Québec, Canada

^cDepartment of Neurosurgery, Medical University of South Carolina, Charleston, SC, USA

Accepted 16 March 2000

Abstract

Objectives: The goal of this study is to provide a better understanding of the role of the cortex in sleep's macro- and microstructure modulation.

Methods: Sleep architecture and phasic events were investigated in 4 patients having undergone right functional or anatomical hemispherectomy and 8 control subjects. Between-groups differences were assessed using the Wilcoxon–Mann–Whitney test.

Results: Findings provide evidence for overall similarity between patients' and control subjects' left hemispheric sleep architecture. In addition, results clearly indicate that it is possible to detect electrical activity over the operated side of a hemispherectomized patient's brain, even when resection of the hemi-cortex has been complete. Finally, findings provide evidence for similar left and right hemispheric relative spectral activities and for an increase in fast activity bands over the intact hemisphere in anatomical hemispherectomized patients.

Conclusions: This study provides evidence that right hemispherectomy does not produce significant sleep architecture alterations as recorded over the intact hemisphere. In addition, residual activity detected over the operated side in anatomical hemispherectomized patients is interpreted as resulting from volume conduction originating from generators located in the intact hemisphere. Finally, there is strong evidence for electrophysiological compensation in the intact hemisphere following complete resection of the contralateral hemi-cortex. © 2000 Elsevier Science Ireland Ltd. All rights reserved.

Keywords: Hemispherectomy; EEG; Sleep spindles; K-complexes; Spectral analyses

1. Introduction

Investigations of sleep following cerebral insult have shed some light on the subcortical mechanisms of human sleep regulation. However, little is yet known about the role of the cortex in normal human sleep.

The temporal organization of states of vigilance depends upon numerous neuronal systems located in the brainstem, hypothalamus, thalamus and basal forebrain (Jones, 1994). Although the cerebral hemispheres do not appear to be primordial in the generation or maintenance of sleep, as illustrated by the case of an anencephalic infant (Nielsen and Sedgwick, 1949), several studies of patients with vascular lesions suggest that higher cerebral structures exert

modulatory influences on the expression of sleep. Patients with extensive cortical laminar necrosis fail to exhibit sleep structure, spindles and slow waves (Autret et al., 1975) and a lack of spindles and an asymmetry of delta and theta waves have been observed following vascular unilateral cortical lesions (Murri et al., 1985). Further, an increase of slow wave sleep (SWS) and a decrease of REM sleep have been reported following unilateral right or left sylvian softening, suggesting that both hemi-cortices may play an important role in sleep modulation (Korner et al., 1986).

Neurological degenerative diseases have also been shown to alter sleep. Alzheimer's disease (AD) has been associated with an increase in the number and duration of awakenings and, therefore, with an increase in the percentage of stage 1 sleep and a decrease in SWS (Loewenstein et al., 1982; Prinz et al., 1982; Reynolds et al., 1985; Bliwise et al., 1989; Hanafusa et al., 1991). In addition, stage 2 sleep spindles and K-complexes have been found to be poorly formed, shorter in duration, and of decreased amplitude and frequency (Prinz et al., 1982; Montplaisir et al.,

* Corresponding author. Centre d'Étude du Sommeil, Hôpital du Sacré-Coeur, 5400 Boulevard Gouin Ouest, Montréal, Québec, Canada H4J 1C5. Tel.: +1-514-338-2222 ext. 3010; fax: +1-514-338-2531.

E-mail address: j-montplaisir@crhs.umontreal.ca (J. Montplaisir).

1985), and decreased REM sleep percentage has been reported in these patients (Loewenstein et al., 1982; Prinz et al., 1982). More striking, however, are reports of REM sleep temporo-parieto-occipital EEG slowing (Petit et al., 1991, 1992). This characteristic of AD patients' sleep has recently been explained by the degeneration of subcortical-cortical cholinergic projections (Petit et al., 1993).

Sleep alterations in epileptic patients provide additional evidence for a cortical influence on sleep mechanisms. Nocturnal partial and generalized seizures disturb sleep profoundly. A decrease in sleep efficiency, an increase in sleep stages 1 and 2, and a decrease in SWS and REM sleep have been repeatedly reported independent of epilepsy type (Angelieri, 1975; Baldy-Moulinier, 1982; Besset, 1982). However, sleep and circadian fluctuations in vigilance have been found to influence in turn the occurrence of seizures, as well as the frequency, morphology, and propagation of interictal activity (Montplaisir et al., 1985). Although these studies suggest that higher cerebral structures influence sleep, such an interpretation of sleep alterations in patients with cortical insult must be taken with caution, due to the complexity of neuronal interference arising from damaged tissue. Investigation of the nocturnal EEG of patients with extensive or complete cortical resection of one hemi-cortex is therefore of particular interest and may well provide additional clues regarding the role of the cerebral hemispheres in sleep regulation.

To our knowledge, there exist only two studies on hemispherectomized patients' sleep in the literature. The first one describes sleep architecture in 7 patients having undergone *functional* (partial) or *anatomical* (complete) hemispherectomy (Mingrino et al., 1969). Although no changes were observed in functional hemispherectomized patients' sleep, anatomical hemispherectomized patients' nocturnal EEG recordings revealed a decrease in the total number of REM-NREM cycles, an increase in stage 2 percentage, an absence of stage 4, and a decrease in REM sleep latency and percentage. This study, however, mentions neither the lateralization of surgery nor control group characteristics. The second study (Itil and Saletu, 1971), describes sleep prints of a patient having undergone left anatomical hemispherectomy, leaving only the thalamus and part of the basal ganglia intact. Digital computer analyses of the EEG revealed that electrical activity could still be detected over the operated side after surgery; further, recorded activity was very similar to that observed over the intact hemisphere, and, in fact, provided sufficient information for sleep staging. Like Mingrino et al. (1969), these authors observed an increase in stage 2 sleep over the intact hemisphere. Unlike the previous authors, however, they also observed an increase in stage 1 sleep, an increase in sleep stages 3 and 4, a decrease of spindles and K-complexes, and no changes in REM sleep latency and percentage over the operated side. Unfortunately, this study did not provide a better understanding of the role of the cortex in sleep modulation, due to the partial resection of the basal ganglia.

However inconsistent the previous findings, and however important they may be to our understanding of cortical influences on sleep, sleep architecture in hemispherectomized patients has not been examined since these two early studies. The goal of the present study was thus two-fold: first, to assess the impact of right hemispherectomy on the macro- and micro-structure of sleep recorded over the intact left hemisphere of patients, and second, to investigate spectral components of sleep EEG signals recorded over the intact and operated hemi-scalps of right anatomical hemispherectomized patients.

2. General method

2.1. Subjects

One male and 3 females (mean age 22.2 years) having undergone anatomical or functional right hemispherectomy participated in the study. The surgical procedure was performed in all patients to alleviate intractable generalized epilepsy. Only one patient (case 3) continued to take medication at the time of investigation to control epileptic activity.

2.1.1. Case 1

C.F., a 14-year-old female, underwent complete removal of the right cortical hemisphere at age 8 years as a last resort to control epileptic seizures resulting from birth trauma. Preoperative CT scan and angiogram revealed an infarcted right cerebral hemisphere in the area of the right middle cerebral artery distribution, an atrophic middle cerebral artery, and some mild asymmetry between the right and left sides of the anterior cerebral and posterior cerebral arteries. An anatomical right hemispherectomy was performed including anterior-to-posterior section of the corpus callosum and dissection anteriorly along the caudate nucleus and posteriorly around the basal ganglion. The entire right cortex was then removed. Since surgery, C.F. had had no seizures. An MRI revealed that the intact hemisphere had slightly shifted in a rotational fashion. Part of the left occipital lobe today occupies the right posterior cavity.

2.1.2. Case 2

T.H., a 22-year-old female, also underwent anatomical right hemispherectomy. Onset of epileptic seizures occurred at 9 years following thrombosis of the right middle cerebral artery secondary to a Tetralogy of Fallot. Surgery was performed the same year as epilepsy onset. The entire right cortex and the subcortical ganglion lateral to the ventricular system were removed. The thalamic portion of the caudate nucleus and part of the hippocampus were left intact. T.H. has had no further seizures since surgery.

2.1.3. Case 3

D.R., a 20-year-old female, underwent right functional

hemispherectomy to alleviate intractable seizures resulting from chronic encephalitis. Surgery was performed at 17 years of age and consisted of a fronto-parieto-temporal craniotomy, an anterior temporal lobectomy, removal of the amygdaloid uncus and of part of the hippocampus, and subtotal lateral callosotomy. Mild, recurrent, motor seizures are today controlled with anti-epileptic medication (Carbamazepine CR 400 mg twice daily).

2.1.4. Case 4

S.E., a 28-year-old male, also underwent right functional hemispherectomy. Onset of seizures occurred at 7 years. CT scan demonstrated a right proencephalic cyst and cerebral parieto-temporal atrophy with some preservation of the medial occipital lobe and right hippocampus. Surgery was performed at 25 years of age and consisted of removal of the cyst, a right fronto-parieto-temporal craniotomy, excision of the amygdala, and partial removal of the hippocampus. S.E. is today free of medication.

2.1.5. Control subjects

Eight control subjects (6 women and two men; mean age 21 years; age range 14–28 years) matched for age, gender, and handedness participated in the study. They were selected on the basis of an absence of a history of sleep, neurological, or psychiatric problems. They were also screened for recent drug or alcohol dependence, and for previous brain injury.

2.2. Methods

2.2.1. Recording and sleep stage scoring

All subjects spent 3 consecutive nights in the sleep laboratory. The first two nights were for adaptation and investigation of REM sleep dream mentation (McCormick et al., 1997). All-night polysomnograms from the third night were investigated in the present study. EOG, mental EMG, and 16 EEG electrodes (Fp1, Fp2, F3, F4, C3, C4, P3, P4, F7, F8, T3, T4, T5, T6, O1, O2) were placed over the scalp surface using the international 10–20 system (Jasper, 1958) as well as the standard montage for sleep staging (Rechtschaffen and Kales, 1968). EEG channels were recorded continuously on a computer system with a linked ear reference. The EEG signals were amplified with a 6 db bandpass of 0.3–100 Hz, digitized at a rate of 256 Hz, and filtered on line with a 64 Hz frequency cut-off digital filter. Following this filtering, only 128 samples per second per channel were stored for analysis. Onset of the nocturnal EEG recordings was defined as the time when lights were turned off. Sleep recordings were scored for sleep stages by an experienced polysomnographer on the basis of the intact left hemisphere, and standard sleep parameters were calculated for a 7 h period. In addition, REM density was scored as the percentage of 2 s mini-epochs of REM sleep containing at least one rapid eye movement (Lapierre and Montplaisir, 1992), and a certified electroencephalographer

visually scanned patients' EEG tracings for detection of any residual epileptic activity.

2.2.2. Measurement of K-complexes and of spindle activity

Four episodes of 15 min each were sampled from stage 2 sleep for counting spindles and K-complexes. These episodes were free of any artifacts and fluctuations in sleep stages and were distributed homogeneously over the 7 h of recording in all subjects. The criterion for spindle activity was that they be visually homogeneous wave periods in the sigma band (12–15 Hz) with a duration of at least 0.5 s (Rechtschaffen and Kales, 1968). K-complexes were defined as large amplitude bi- or triphasic slow waves of at least 75 μ V and of a duration of 0.5–3 s (Declercq et al., 1987). An experienced polysomnographer and a certified technician, both of whom had extensive experience in scoring stage 2 phasic events, identified all spindles and K-complexes by visually scanning all channels separately in order to prevent any influence of the simultaneous occurrence of phasic events in several regions. All channels were then displayed together in order to count in turn the total number of spindles and the total number of K-complexes having occurred simultaneously and in any combination of channels. This approach made possible the determination of the total number of generated events regardless of their topographical location. Inter-judge reliability was at least 90% for identifying spindles, and was within the 80–85% range for K-complexes. Finally, the mean density per minute and the mean duration of spindles and K-complexes were calculated for patients and control subjects.

2.2.3. Spectral analyses

Spectral analyses were performed on samples of anatomical hemispherectomized patients' stage 2 sleep and REM sleep. The linked-ear referential montage was reformatted to a bipolar coronal montage (Fp1-F3, Fp2-F4, F3-C3, F4-C4, C3-P3, C4-P4, P3-O1, P4-O2, Fp1-F7, Fp2-F8, F7-T3, F8-T4, T3-T5, T4-T6, T5-O1, T6-O2) to eliminate the possible influence of the reference electrodes. Samples consisted of the first 5 sections of 4 s of stage 2 sleep and REM sleep that were free of muscular and ocular artifacts in each of the first, second, and third complete REM-NREM sleep cycles. The total sample size was thus 60 s for each sleep stage. Spectral analyses were performed using a commercial software package, Rhythm 10.1 (Stellate Systems Reg, Montréal, 1996), which computes the fast Fourier transform on 4 s epochs with a resolution of 0.25 Hz and cosine window smoothing. Frequency bands were defined as follows: delta (0.75–3.75 Hz), theta (4.00–7.75 Hz), alpha (8.00–12.75 Hz), beta 1 (13.00–19.75 Hz), and beta 2 (20.00–30.00 Hz). Three types of measure were calculated: (1) absolute and relative power per derivation in each frequency band; (2) total activity per derivation; and (3) hemispheric asymmetry indices for homologous left and right derivations. The latter measure was defined as the

Table 1
Sleep parameters for right hemispherectomized patients and control subjects

	TST (min)	Sleep latency (min)	Sleep efficiency (min)	Stage 1 (%)	Stage 2 (%)	Stage 3 (%)	Stage 4 (%)	REM (%)	REM latency (%)	REM density (%)
Patients										
C.F.	403.70	5.30	97.00	4.00	50.90	15.90	5.50	23.70	63.70	27.93
T.H.	321.00	10.30	78.40	7.60	56.40	15.60	0.20	20.20	59.00	27.84
D.R.	413.30	0.00	98.20	5.40	66.50	9.40	1.30	17.30	61.00	27.67
S.E.	375.00	27.30	95.60	11.60	65.40	0.00	0.00	23.00	86.30	29.22
Mean	378.25	10.73	92.30	7.15	59.80	10.23	1.75	21.05	67.50	28.17
SD	41.49	11.82	9.33	3.32	7.46	7.45	2.56	2.92	12.68	0.71
Controls										
A.P.	396.30	19.00	98.80	4.30	51.70	10.40	15.50	18.00	157.70	29.20
A.T.	417.70	1.30	99.80	3.60	63.40	9.30	6.90	16.40	70.00	15.10
J.D.	410.30	2.70	98.20	3.60	57.50	8.50	6.40	24.00	79.30	35.88
V.E.	398.00	9.70	97.00	8.50	47.90	11.60	6.70	25.10	64.30	17.71
G.F.	410.00	2.30	98.20	4.70	57.90	12.30	1.20	23.70	74.70	28.22
I.G.	412.30	8.00	100.00	4.90	50.80	8.00	6.50	29.70	59.70	31.94
M.H.	411.70	6.30	99.50	9.60	58.50	10.10	0.60	20.00	69.30	19.60
Y.P.	414.70	2.30	99.30	5.60	57.00	4.70	0.00	31.60	62.70	16.41
Mean	408.88	6.45	98.85	5.60	55.59	9.36	5.48	23.56	79.71	24.26
SD	7.66	5.92	1.01	2.25	5.04	2.38	5.04	5.34	32.15	7.97
P value	0.21	0.65	0.02	0.43	0.46	0.56	0.16	0.36	0.30	0.80

difference between left and right total activities (left total_{abs.} – right total_{abs.}).

2.3. Statistical analyses

Between-groups differences were assessed by comparing populations' rankings of data for each sleep architecture variable examined and for the mean density and the mean duration of spindles and K-complexes. This was achieved by using the Wilcoxon–Mann–Whitney test. Statistical comparisons were based upon a two-tailed probability cut-off level ($\alpha = 0.05$).

3. Results

3.1. Overall brain electrical activity

Visual scanning of bipolar recordings of both functional and anatomical hemispherectomized patients revealed the absence of residual epileptic spikes. In addition, electrical activity was observed over the operated side, although a marked decrease in amplitude was noted both over right resected cortical areas in functional hemispherectomized patients, and over the entire right hemi-scalp in anatomical hemispherectomized patients.

3.2. Sleep structure

3.2.1. Sleep macro-structure

Patients' intact left hemispheres' sleep macro-structure did not markedly differ from that of control subjects

(Table 1). No differences between patients and control subjects were observed with respect to sleep latency and total sleep time (TST). In addition, no differences between groups were noted for the percentage of time spent in the various stages of non-REM sleep, as well as for REM sleep latency, the number of REM periods, the percentage of time spent in REM sleep, and the percentage of REM sleep density. Although an overall decrease in sleep efficiency ($P = 0.02$) was observed, this result was attributed to T.H.'s low score (78.4%).

3.2.2. Sleep micro-structure

Similarly to results of the sleep macro-structure analyses, patients and control subjects did not differ with respect to sleep micro-structure as recorded over the intact left hemisphere (Table 2). No differences between groups were observed for the mean density of spindles and for K-complexes. In addition, patients' mean durations of spindles and of K-complexes were similar to those of control subjects.

Remaining activity recorded over the right hemi-scalp of patients having undergone complete resection of the right hemisphere was characterized by the presence of stage 2 spindles and K-complexes (Fig. 1). Spindle amplitude was greatest over Fp2-F8 for patient C.F., and over F8-T4 and T3-T5 for patient T.H. K-complexes were systematically observed over pre-frontal and frontal derivations in both patients (Fp2-F4; Fp2-F8; F4-C4), and were occasionally noted over T6-O2 for C.F., and over F8-T4 for T.H. Amplitude and morphology were best preserved over pre-frontal and frontal leads.

Table 2

Mean density and duration of phasic events over the left hemisphere for right hemispherectomized patients and control subjects

	Spindles		K-complexes	
	Mean density (nb/mn)	Mean duration (s)	Mean density (nb/mn)	Mean duration (s)
Patients				
C.F.	5.65	0.83	2.23	0.85
T.H.	12.17	0.98	3.38	0.85
D.R.	10.07	1.15	0.77	0.90
S.E.	7.28	0.73	0.95	0.85
Mean	8.79	0.92	1.83	0.86
SD	2.90	0.18	1.22	0.02
Controls				
A.P.	5.85	0.88	1.67	0.90
A.T.	2.60	0.78	3.93	0.93
J.D.	7.13	1.08	3.58	0.83
V.E.	5.13	0.80	2.93	0.80
G.F.	6.53	0.88	2.22	0.68
I.G.	8.17	1.15	1.08	0.75
M.H.	3.62	0.80	2.22	0.80
Y.P.	3.20	0.78	0.77	0.78
Mean	5.28	0.89	2.30	0.81
SD	2.00	0.14	1.13	0.08
<i>P</i> value	0.07	0.86	0.38	0.47

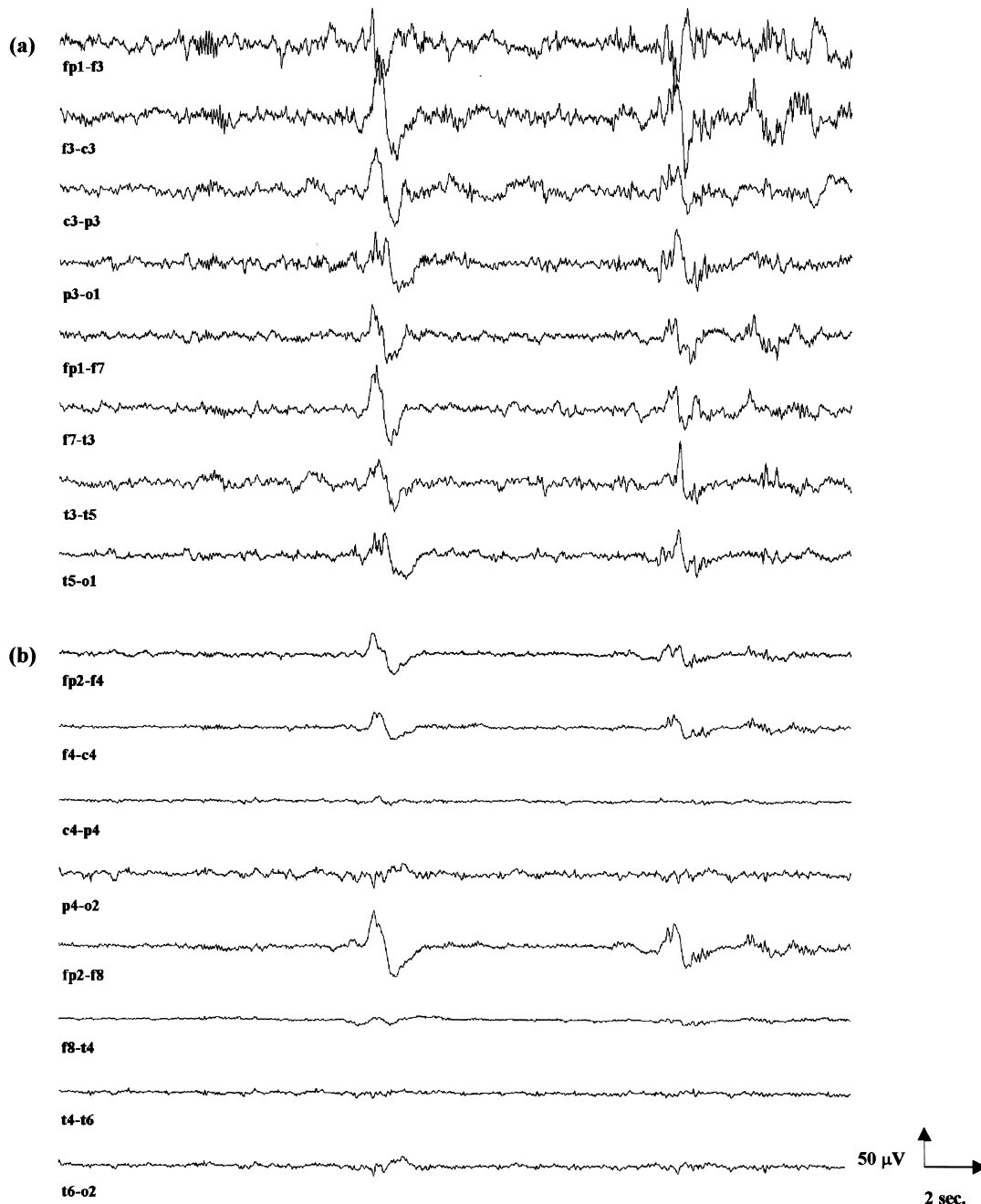


Fig. 1. Characteristic sample of right anatomical hemispherectomized patients' sleep EEG over (a) left and (b) right channels.

3.3. Spectral analyses

Spectral analyses of stage 2 sleep and REM sleep showed, as expected, that anatomical hemispherectomized patients had larger hemispheric asymmetry scores than control subjects. Differences were most marked over frontal, central, and temporal derivations (Fp1F3-Fp2F4; F3C3-F4C4; F7T3-F8T4; T3T5-T4T6) (Fig. 2).

These larger asymmetry scores resulted from an overall decrease in total activity detected over the operated side and

from an overall increase in total activity recorded over the intact hemisphere in both patients relative to controls (Table 3). The overall increase in total activity over the intact hemisphere was further attributed to a predominant increase in beta 1 and beta 2 activity bands for C.F., and to an increase in all activity bands for T.H.

Finally, similar left and right relative activities for all frequency bands were observed during stage 2 sleep and REM sleep in both anatomical hemispherectomized patients (Tables 4 and 5).

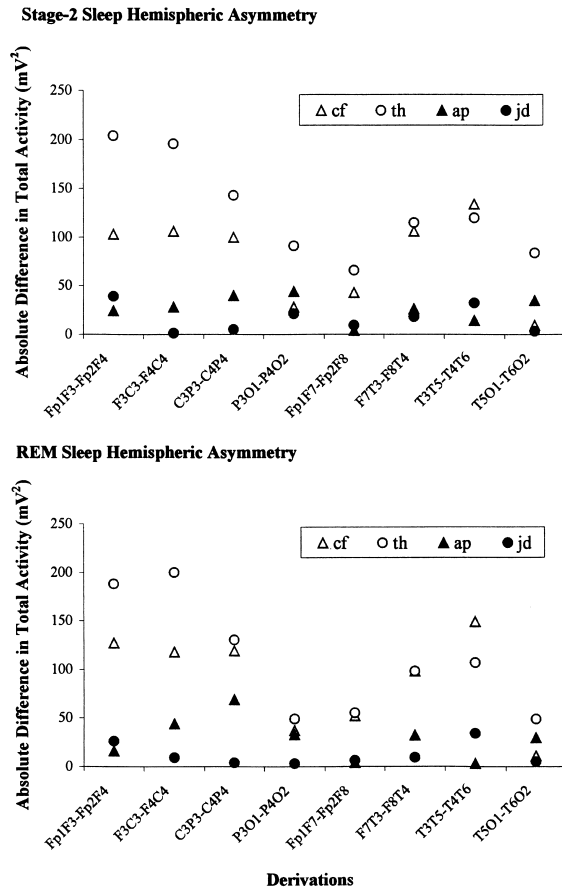


Fig. 2. Stage 2 sleep and REM sleep hemispheric asymmetry indices of anatomical hemispherectomized patients (C.F. and T.H.) and control subjects (A.P. and J.D.).

4. Discussion

Results of the present study provide evidence for overall similarity between right hemispherectomized patients' and control subjects' left hemispheric sleep architecture. In addition, results clearly indicate that it is possible to detect electrical activity over the operated side of a hemispherectomized patient's brain, even when resection of the hemi-cortex has been total. Finally, findings provide evidence for similar left and right hemispheric relative spectral activities and for an increase in fast activity bands over the intact hemisphere in anatomical hemispherectomized patients when compared to control subjects.

Table 3

Total REM sleep spectral activity per laterality and derivation in anatomical hemispherectomized patients (C.F. and T.H.) and respective control subjects

	C.F.		Controls		T.H.		Controls	
	LH	RH	LH	RH	LH	RH	LH	RH
Fp1-F3/Fp2-F4	216	89	168	185	264	76	115	141
F3-C3/F4-C4	168	50	189	233	258	56	114	123
C3-P3/C4-P4	191	72	224	155	180	50	148	144
P3-O1/P4-O2	137	100	203	236	160	111	162	165
Fp1-F7/Fp2-F8	158	106	116	120	140	85	109	115
F7-T3/F8-T4	160	62	152	185	150	52	114	123
T3-T5/T4-T6	203	54	173	173	167	60	111	145
T5-O1/T6-O2	124	115	177	207	125	76	164	159

tomized patient's brain, even when resection of the hemi-cortex has been total. Finally, findings provide evidence for similar left and right hemispheric relative spectral activities and for an increase in fast activity bands over the intact hemisphere in anatomical hemispherectomized patients when compared to control subjects.

4.1. Sleep architecture

Differences between results of previous investigations of sleep architecture in hemispherectomized patients (Mingrino et al., 1969; Itil and Saletu, 1971) and those of the present study may well result from the highly controlled selection of patients and control subjects having participated in our study. Three out of 4 of our patients were free of seizures and of medication at the time of the investigation, whereas surgical outcome of patients having participated in previous studies was not reported.

The observation of overall similarity between hemispherectomized patients' and control subjects' sleep architecture as recorded over the intact left hemisphere has several implications. First, it demonstrates the efficacy of hemispherectomy in controlling the occurrence of epileptic activity in some extreme cases of secondary generalized epilepsy. It is today well known that SWS activation of thalamo-cortical synchronization mechanisms facilitates the occurrence of bilateral generalized epileptic activity (Gastaut et al., 1962; Pompeiano, 1969; Montplaisir, 1990; Touchon et al., 1991; Baldy-Moulinier, 1994). The fact that SWS does not trigger any such activity in our patients strongly suggests that all epileptic foci have been successfully resected. Second, the similarity in sleep architecture between our patients and control subjects suggests that the right hemi-cortex does not influence the expression of sleep structure as recorded over the left hemisphere. This interpretation is consistent with the consensus among scientists according to which nocturnal EEG cycles and rhythms are regulated by subcortical mechanisms rather than by cortical neuronal networks (Steriade and McCarley, 1990). In addition, between-groups similarities for mean density and duration of stage 2 spindles and K-complexes as recorded over the left hemisphere suggest that the right hemi-cortex does not influence the expression of these phasic events. However, it is also possible that under normal circumstances both hemispheres have an influence on subcortical areas primarily responsible for sleep control, and that following hemispherectomy, brain plasticity allows the intact side to increase its influence upon subcortical structures in order to compensate for the loss of the removed hemispheres' modulatory impact.

4.2. Origin of the electrical activity recorded over the operated hemi-cortex

Results of the present study confirm previous reports that it is possible to detect electrical activity over the operated side of a hemispherectomized patients' brain even when

Table 4
Anatomical hemispherectomized patients' relative spectral activities during stage 2 sleep

	Patient C.F.						Patient T.H.					
	Delta	Theta	Alpha	Beta 1	Beta 2	Sigma	Delta	Theta	Alpha	Beta 1	Beta 2	Sigma
Fp1-F3	30.7	19.8	17.0	16.5	16.0	9.1	28.4	18.8	23.3	19.4	10.1	13.9
Fp2-F4	30.3	20.2	16.8	18.8	13.9	8.8	31.0	21.6	23.4	13.4	10.7	10.9
F3-C3	29.3	19.4	18.2	17.9	15.1	8.2	29.2	17.8	23.1	18.5	11.4	11.4
F4-C4	33.6	20.2	16.3	16.3	13.7	7.5	28.7	19.9	24.7	16.7	10.1	11.6
C3-P3	30.0	21.7	15.3	18.8	14.2	6.4	34.6	19.3	20.1	16.6	9.3	9.7
C4-P4	31.2	19.4	15.2	20.8	13.4	6.6	33.6	19.8	19.0	16.4	11.2	7.9
P3-O1	33.7	21.4	17.3	15.5	12.2	6.5	26.7	20.8	20.1	22.3	10.1	11.8
P4-O2	29.1	21.8	18.7	18.4	12.0	6.6	33.9	22.9	18.9	13.6	10.6	7.0
Fp1-F7	28.8	16.6	18.0	19.6	17.1	9.0	31.1	18.2	22.2	16.7	11.9	10.2
Fp2-F8	30.7	17.7	17.5	20.3	13.8	9.5	29.9	18.7	26.0	15.8	9.6	12.4
F7-T3	27.0	17.1	17.9	21.2	16.7	9.0	31.1	18.8	23.5	15.5	11.0	10.8
F8-T4	28.4	18.0	14.8	23.2	15.7	6.7	34.0	19.4	20.4	14.5	11.7	8.6
T3-T5	33.6	21.0	16.7	16.5	12.2	6.0	34.4	22.3	19.0	14.7	9.6	8.5
T4-T6	29.5	17.1	15.4	22.7	15.3	7.3	31.2	21.4	19.4	15.7	12.3	8.1
T5-O1	31.5	19.8	16.4	18.2	14.1	7.1	31.1	22.5	20.4	15.4	10.6	8.5
T6-O2	28.1	23.3	17.9	19.0	11.8	6.7	31.8	21.1	18.9	16.8	11.4	8.7

resection of the hemi-cortex has been total (Marshall and Walker, 1950; Obrador and Larramendi, 1950; Cobb and Pampiglone, 1952; Ueki, 1966; Lorenz et al., 1968; Mingrino et al., 1969; Itil and Saletu, 1971). The source of remaining electrical brain activity recorded over the operated side of anatomical hemispherectomized patients has, however, been a source of debate. Some authors have postulated that this activity is only an echo of the intact hemisphere's activity (Cobb and Sears, 1960), while others have suggested that it comes from both the intact hemisphere and subcortical structures (Itil and Saletu, 1971). Therefore, we investigated and compared spectral components of sleep EEG signals recorded over the intact and operated hemispheres of anatomical hemispherectomized patients in an attempt to determine the nature and origin of electrical

activity detected over the right cavity. Results revealed similar left and right hemispheric relative activities, a finding which is consistent with the hypothesis that activities detected over the operated side come primarily from generators located in the intact hemisphere. The observed decrease in total absolute activity recorded over the operated side was thus attributed to propagation of the intact hemisphere's electrical activity through different volume conductors, since the resected cortex was replaced with cerebrospinal fluid in both patients.

4.3. Spectral components of brain activity recorded over the intact hemisphere

Finally, an increase in activity of fast frequency bands

Table 5
Anatomical hemispherectomized patients' relative spectral activities during REM sleep

	Patient C.F.						Patient T.H.					
	Delta	Theta	Alpha	Beta 1	Beta 2	Sigma	Delta	Theta	Alpha	Beta 1	Beta 2	Sigma
Fp1-F3	28.9	21.3	10.7	19.0	20.1	5.5	31.2	22.4	15.1	14.5	16.8	5.6
Fp2-F4	31.3	20.4	13.8	18.6	15.9	5.9	30.3	20.8	15.2	14.7	19.1	5.9
F3-C3	25.6	21.0	13.5	17.4	22.5	5.0	25.3	21.9	17.4	17.1	18.2	6.9
F4-C4	31.9	21.7	14.3	15.8	16.3	5.1	30.9	22.9	16.1	13.7	16.3	5.7
C3-P3	31.6	20.5	15.3	15.8	16.8	5.2	28.1	23.2	20.7	15.1	12.9	5.7
C4-P4	32.1	21.5	15.5	16.3	14.5	5.9	31.8	21.6	18.6	13.8	14.1	5.5
P3-O1	33.9	23.5	14.9	15.7	12.1	5.4	25.2	25.7	21.5	14.3	13.4	6.3
P4-O2	30.6	23.9	17.7	15.3	12.6	5.8	32.2	23.7	18.9	13.6	11.5	6.3
Fp1-F7	31.1	17.1	11.3	19.3	21.1	5.2	31.4	21.9	14.6	14.8	17.3	5.0
Fp2-F8	34.2	18.5	12.8	19.2	15.4	6.5	37.5	18.9	13.1	12.8	17.7	5.1
F7-T3	29.9	17.9	12.2	18.9	21.1	5.2	26.8	20.9	16.5	16.1	19.7	6.3
F8-T4	38.0	18.3	13.2	17.7	12.9	6.2	40.3	17.2	14.6	13.1	14.8	5.4
T3-T5	34.3	21.4	15.6	15.4	13.3	5.1	33.5	21.9	19.1	13.4	12.2	5.5
T4-T6	30.4	19.7	15.3	18.5	16.2	6.5	31.4	21.1	18.9	14.9	13.8	6.4
T5-O1	32.7	21.4	15.4	15.3	15.3	5.4	27.3	25.3	19.6	14.6	13.2	6.3
T6-O2	30.8	23.5	18.2	15.0	12.5	5.9	33.1	22.0	18.8	14.0	12.1	5.8

was observed over the intact hemisphere of both of the anatomical hemispherectomized patients when compared to control subjects during stage 2 sleep and REM sleep. This fact strongly suggests that electrophysiological compensation has taken place following surgery. This hypothesis is consistent with results of single photon emission computerized tomography (SPECT) and positron emission tomography (PET) investigations of anatomical hemispherectomized patients. The latter have indeed respectively demonstrated increases in glucose metabolism and in blood flow within the intact hemisphere following surgery (Pawlik et al., 1990; Carmant et al., 1994).

Overall, this investigation provides evidence that right hemispherectomy does not produce significant sleep architecture alterations as recorded over the intact hemisphere. In addition, findings suggest that electrical activities detected over the operated side in anatomical hemispherectomized patients originate primarily from generators located in the intact hemisphere. Finally, results provides strong evidence for electrophysiological compensation in the intact hemisphere following complete resection of the contralateral hemi-cortex.

Acknowledgements

This research was supported by the 'Fonds de la Recherche en Santé du Québec' and by the Medical Research Council of Canada. The authors wish to thank C.F., T.H., D.R., and S.E. for their cooperation in this study, as well as Sylvie Rompré, Jean Paquet, PhD, and Farid Hassainia, PhD for their assistance in parts of this study.

References

- Angelieri F. Partial epilepsies and nocturnal sleep. In: Levin P, Koella WP, editors. *Sleep*. Basel: Karger, 1975. pp. 196–203.
- Autret A, Carrier H, Thommasi M, Jouvét M, Schott B. Étude physiopathologique et neuropathologique d'un syndrome de décortication cérébrale. *Rev Neurol* 1975;131:491–504.
- Baldy-Moulinier M. Temporal lobe epilepsy and sleep organization. In: Serman MB, Passouant P, editors. *Sleep and epilepsy*, New York: Academic Press, 1982. pp. 347–359.
- Baldy-Moulinier M. Les épilepsies de la nuit. In: Billard M, editor. *Le sommeil normal et pathologique*, Paris: Masson, 1994. pp. 443–453.
- Besset A. Influence of generalized seizures on sleep organization. In: Serman MB, Passouant P, editors. *Sleep and epilepsy*, New York: Academic Press, 1982. pp. 339–346.
- Bliwise DL, Tinklenberg J, Yesavage JA. REM latency in Alzheimer's disease. *Biol Psychiatr* 1989;25:320–328.
- Carmant L, O'Tuama LA, Roach PJ, Kramer U, Mikati MA, Riviello JJ, Helmers SL, Madsen JR, Black PM, Lombroso CT, et al. Technetium-99m HmPAO brain SPECT and outcome of hemispherectomy for intractable seizures. *Pediatr Neurol* 1994;11:203–207.
- Cobb WA, Pampiglone G. The electroencephalogram in relation to human cerebral hemispherectomy. *Rev Neurol* 1952;87:465.
- Cobb W, Sears TA. A study in the transmission of potentials after hemispherectomy. *Electroenceph clin Neurophysiol* 1960;12:371–383.
- Declerck AC, Arends J, Wauquier A. Phasic events and clinical practice. *Clin Neurol Neurosurg* 1987;89:152–154.
- Gastaut H, Batini C, Fressy J. A propos des crises épileptiques enregistrées au cours du sommeil nocturne chez l'enfant. *Rev Neurol* 1962;107:276.
- Hanafusa H, Motomura N, Fukai M. Event-related potentials in senile dementia of Alzheimer type, multiinfarct dementia and Parkinson's disease. *Jpn J Psychiatr Neurol* 1991;45:667–670.
- Itil TM, Saletu B. Digital computer analyzed resting and sleep EEGs (sleep prints) after hemispherectomy in man. *Electroenceph clin Neurophysiol* 1971;30:457–461.
- Jasper HH. The ten-twenty electrode system of the international federation. *EEG Clin Neurophysiol* 1958;10:322–339.
- Jones BE. Basic mechanisms of sleep-wake states. In: Kryger MH, Roth T, Dement WC, editors. *Principles and practice of sleep medicine*, London: W.B. Saunders, 1994. pp. 145–162.
- Korner E, Flooh E, Reinhart B, Wolf R, Ott E, Krenn W. Sleep alterations in ischemic stroke. *Eur Neurol* 1986;25:104–110.
- Lapierre O, Montplaisir J. Polysomnographic features of REM sleep behavior disorder: development of a scoring method. *Neurology* 1992;42:1371–1374.
- Loewenstein RJ, Weingartner H, Gillin JC, Kaye W, Ebert M, Mendelson WB. Disturbances in sleep and cognitive functioning in patients with dementia. *Neurobiol Aging* 1982;3:371–377.
- Lorenz R, Grützner A, Vogelsang H. Elektroencephalographische Befunde bei hemisphärektomierten Patienten. *Dtsch Z Nervenheilk* 1968;193:18–40.
- Marshall C, Walker AE. The electroencephalographic changes after hemispherectomy in man. *Electroenceph clin Neurophysiol* 1950;2:147–156.
- McCormick L, Nielsen T, Pfito M, Hassainia F, Pfito A, Vera C, Montplaisir J. REM sleep dream mentation in right hemispherectomized patients. *Neuropsychologia* 1997;35:695–701.
- Mingrino S, Semerano A, Ravenna C, Benedetti A. Nocturnal EEG patterns of patients following complete or partial hemispherectomy. *Electroenceph clin Neurophysiol* 1969;27:96–103.
- Montplaisir J. Epilepsy and sleep: reciprocal interactions and diagnostic procedures involving sleep. In: Thorpy MJ, editor. *Handbook of sleep disorders*, New York: Marcel Dekker, 1990. pp. 260–268.
- Montplaisir J, Laverdière M, Saint-Hilaire JM. Sleep and epilepsy. In: Gotman J, Ives JR, Gloor P, editors. *Long-term monitoring in epilepsy EEG*, Amsterdam: Elsevier, 1985. pp. 215–239.
- Murri L, Massetani G, Siciliano L, Giovanditti L, Arena R. Dream recall after sleep interruption in brain-injured patients. *Sleep* 1985;8:356–362.
- Nielsen JM, Sedgwick RP. Instincts and emotions in an anencephalic monster. *J Ment Dis* 1949;110:387–394.
- Obrador S, Larramendi MH. Some observations on the brain rhythms after surgical removal of a cerebral hemisphere. *Electroenceph clin Neurophysiol* 1950;2:143–146.
- Pawlik G, Holthoff VA, Kessler J, Rudolf J, Hebold IR, Lottgen J. Positron emission tomography findings relevant to neurosurgery for epilepsy. *Acta Neurochirurg* 1990;50:84–87.
- Petit D, Lorrain D, Gauthier S, Montplaisir J. EEG spectral analysis in Alzheimer's disease: EEG slowing more prominent during REM sleep than during wakefulness. *Sleep* 1991;20:392.
- Petit D, Montplaisir J, Lorrain D, Gauthier S. Spectral analysis of the rapid eye movement sleep electroencephalogram in right and temporal regions: a biological marker of Alzheimer's disease. *Ann Neurol* 1992;32:172–176.
- Petit D, Lorrain D, Gauthier S, Montplaisir J. Regional spectral analysis of the REM sleep EEG in mild to moderate Alzheimer's disease. *Neurobiol Aging* 1993;14:141–145.
- Pompeiano O. Sleep mechanisms. In: Jasper HH, Ward AA, Pope A, editors. *Basic mechanisms of the epilepsies*, Boston, MA: Little Brown, 1969. pp. 453–473.
- Prinz PN, Peskind ER, Vitaliano PP. Changes in the sleep and waking EEGs of nondemented and demented elderly subjects. *J Am Ger Soc* 1982;30:86–93.
- Rechtschaffen A, Kales A. A manual of standardized terminology, techni-

- ques and scoring system for sleep stages in human subjects, Washington, DC: Public Health Series, US Government Printing Office, 1968.
- Reynolds CF, Kupfer DJ, Taska LS. EEG sleep in elderly depressed, demented, and healthy subjects. *Biol Psychiatr* 1985;20:431–442.
- Steriade M, McCarley RW. Brainstem control of wakefulness and sleep, New York: Plenum Press, 1990.
- Touchon J, Baldy-Moulinier M, Billard M, Besset A, Cadilhac J. Sleep organization and epilepsy. In: Degen R, Rodin EA, editors. *Epilepsy, sleep, and sleep deprivation*, Amsterdam: Elsevier, 1991. pp. 73–81.
- Ueki K. Hemispherectomy in the human with special reference to the preservation of function. In: Tokizane T, Schadé JP, editors. *Correlative neurosciences – part B: clinical studies*, Amsterdam: Elsevier, 1966. pp. 285–338.